

# A Germline Mutation in *BLOC1S3*/Reduced Pigmentation Causes a Novel Variant of Hermansky-Pudlak Syndrome (HPS8)

Neil V. Morgan,<sup>1</sup> Shanaz Pasha,<sup>1</sup> Colin A. Johnson,<sup>1</sup> John R. Ainsworth,<sup>3,4</sup>  
Robin A. J. Eady,<sup>7</sup> Ban Dawood,<sup>2</sup> Carole McKeown,<sup>5</sup> Richard C. Trembath,<sup>8</sup>  
Jonathan Wilde,<sup>6</sup> Steve P. Watson,<sup>2</sup> and Eamonn R. Maher<sup>1,5</sup>

<sup>1</sup>Section of Medical and Molecular Genetics and <sup>2</sup>Centre for Cardiovascular Sciences, Division of Medical Sciences, Institute of Biomedical Research, University of Birmingham, <sup>3</sup>Birmingham Midlands Eye Hospital, <sup>4</sup>Birmingham Childrens' Hospital, <sup>5</sup>West Midlands Regional Genetics Service, Birmingham Women's Hospital, and <sup>6</sup>West Midlands Adult Haemophilia Centre, University Hospital Birmingham, Birmingham, United Kingdom; <sup>7</sup>Genetic Skin Disease Group, St. John's Institute of Dermatology, St. Thomas' Hospital, London; and <sup>8</sup>Division of Medical Genetics, Departments of Medicine and Genetics, University of Leicester, Leicester, United Kingdom

Hermansky-Pudlak syndrome (HPS) is genetically heterogeneous, and mutations in seven genes have been reported to cause HPS. Autozygosity mapping studies were undertaken in a large consanguineous family with HPS. Affected individuals displayed features of incomplete oculocutaneous albinism and platelet dysfunction. Skin biopsy demonstrated abnormal aggregates of melanosomes within basal epidermal keratinocytes. A homozygous germline frameshift mutation in *BLOC1S3* (p.Gln150ArgfsX75) was identified in all affected individuals. *BLOC1S3* mutations have not been previously described in patients with HPS, but *BLOC1S3* encodes a subunit of the biogenesis of lysosome-related organelles complex 1 (BLOC-1). Mutations in other BLOC-1 subunits have been associated with an HPS phenotype in humans and/or mouse, and a nonsense mutation in the murine orthologue of *BLOC1S3* causes the *reduced pigmentation* (*rp*) model of HPS. Interestingly, eye pigment formation is reported to be normal in *rp*, but we found visual defects (nystagmus, iris transillumination, foveal hypoplasia, reduced visual acuity, and evidence of optic pathway misrouting) in affected individuals. These findings define a novel form of human HPS (HPS8) and extend genotype-phenotype correlations in HPS.

Hermansky-Pudlak syndrome (HPS [MIM 203300]) is an autosomal recessive disorder characterized by oculocutaneous albinism and a bleeding diathesis secondary to a platelet storage-pool deficiency caused by a lack of dense bodies in platelets (Hermansky and Pudlak 1959). HPS is genetically heterogeneous, and the severity of skin, hair, and iris hypopigmentation and visual impairment is variable. In addition, some patients develop granulomatous colitis or pulmonary fibrosis (Davies and Tuddenham 1976; Schinella et al. 1980; Sandberg-Gertzen et al. 1999). To date, HPS has been associated with mutations in seven human genes—*HPS1* (mouse model *pale ear*) (MIM 604982), *AP3B1/HPS2* (*pearl*) (MIM 603401), *HPS3* (*cocoa*) (MIM 606118), *HPS4* (*light ear*) (MIM 606682), *HPS5* (*ruby-eye 2*) (MIM 607521), *HPS6* (*ruby-eye*) (MIM 607522), and *HPS7/Dysbindin* (*sandy*) (MIM 607145) (see studies by Dell'Angelica [2004] and Li et al. [2004] and references

therein). In addition, genes have been identified for an additional nine mouse models of HPS that have not yet been described in humans (*mocha*, *pallid*, *gunmetal*, *ashen*, *muted*, *buff*, *subtle gray*, *cappuccino*, and *reduced pigmentation* [*rp*]) (Dell'Angelica 2004; Li et al. 2004).

HPS appears to be a disorder of defective transport of specialized organelles, such that the clinical symptoms of hypopigmentation and impaired visual acuity (VA), prolonged bleeding times, and fibrotic lung disease are caused by abnormal functions of melanosomes, platelet-dense granules, and lysosomes, respectively. HPS2 is caused by mutations in the  $\beta$ 3A subunit of the heterotetrameric AP-3 adapter complex that recruits cargo proteins into clathrin vesicles for transport away from a donor membrane within the Golgi apparatus, plasma membrane, and/or endosomal compartments (Dell'Angelica et al. 1999). In addition, mutations in genes for the murine HPS models *gunmetal* (encoding Rab ger-

---

Received August 25, 2005; accepted for publication October 20, 2005; electronically published November 28, 2005.

Address for correspondence and reprints: Dr. E. R. Maher, Section of Medical and Molecular Genetics, University of Birmingham, Institute of Biomedical Research, Edgbaston, Birmingham, B15 2TT, United Kingdom. E-mail: E.R.Maher@bham.ac.uk  
*Am. J. Hum. Genet.* 2006;78:160–166. © 2005 by The American Society of Human Genetics. All rights reserved. 0002-9297/2006/7801-0018\$15.00

anlygeranyl transferase), *ashen* (encoding Rab27A), and *buff* (encoding VPS33A) are implicated in intracellular vesicular trafficking (Dell'Angelica 2004). Other HPS genes encode components of three protein complexes of unknown function: biogenesis of lysosome-related organelles complex (BLOC)-1, BLOC-2, and BLOC-3. BLOC-2 comprises HPS6/ruby-eye, HPS5/ruby-eye-2, and HPS3/cocoa, and BLOC-3 includes HPS1/pale ear and HPS4/light ear. BLOC-1 was initially found to consist of four proteins (pallidin, muted, cappuccino, and HPS7/sandy) (Falcon-Perez et al. 2002). Recently, however, four additional BLOC-1 subunits were identified (snapin, BLOS1, BLOS2, and BLOS3), and a nonsense mutation in *bloc1s3* was found in the *rp* mouse (Gwynn et al. 2004; Starcevic and Dell'Angelica 2004). We used an autozygosity mapping strategy to map a gene for HPS (*HPS8*) to 19q13 and then identified a germline *BLOC1S3* mutation that causes a novel form of human HPS.

The proband (IV:7; see fig. 1) was referred at age 21 years for genetic counseling for “oculocutaneous albinism.” He was born with silvery hair to Pakistani parents who were first cousins. His hair had slowly darkened to a “gold” color, and he had hazel eyes and pale skin that became red but did not tan in the sun (see fig. 2). At that time, no history of bleeding or recurrent infections was volunteered. On examination, there was generalized hypopigmentation and reduced VA (right VA [RVA] 6/60 and left VA [LVA] 6/60) with pendular nystagmus and iris transillumination (see fig. 2). Eye examination revealed optic disc cupping, pale fundi, and moderate foveal hypoplasia. Visual evoked responses demonstrated increased chiasmatal decussation. There was moderate hypermetropia with esotropia. A scalp skin biopsy performed at age 24 years revealed aggregates of abnormally small but fully melanized melanosomes (see fig. 2).

His second cousin (IV:2) was reviewed at age 12 years. She had light-gold hair, hazel irises, pendular nystagmus, iris transillumination, foveal hypoplasia, hypermetropic astigmatism (corrected VA 6/60 in each eye), and generalized skin hypopigmentation and did not tan in the sun. She developed an antecubital hematoma following venesection, but platelet function studies were not performed at that time. Subsequently, a history of menorrhagia was elicited.

IV:5, sister of the proband, was seen initially at age 15 years. She was reviewed at age 23 years, by which time she had married a first cousin and had two children, one of whom (V:1) was affected. She has incomplete oculocutaneous albinism with silvery hair, generalized depigmentation, hazel irises, nystagmus, exotropia, and high myopia, with VA of 6/36 in each eye.

IV:6 was seen at age 16 years. He was reported to

have cream-colored hair as a baby—but it had darkened—and to have generalized depigmentation, pendular nystagmus, iris transillumination, foveal hypoplasia, and high hypermetropia (corrected RVA 6/120 and LVA 6/60). After IV:13 received the diagnosis of HPS (see below), IV:6 underwent hematological review, and a history of lifelong easy bruising and prolonged bleeding from cuts was elicited. In addition, he described frequent nose bleeds during childhood into early adulthood, which required nasal cautery at age 23 years, and prolonged bleeding from a surgical wound after removal of a lesion from his left thigh at age 11 years. He also reported a history of bilateral frozen shoulder and Peyronie disease.

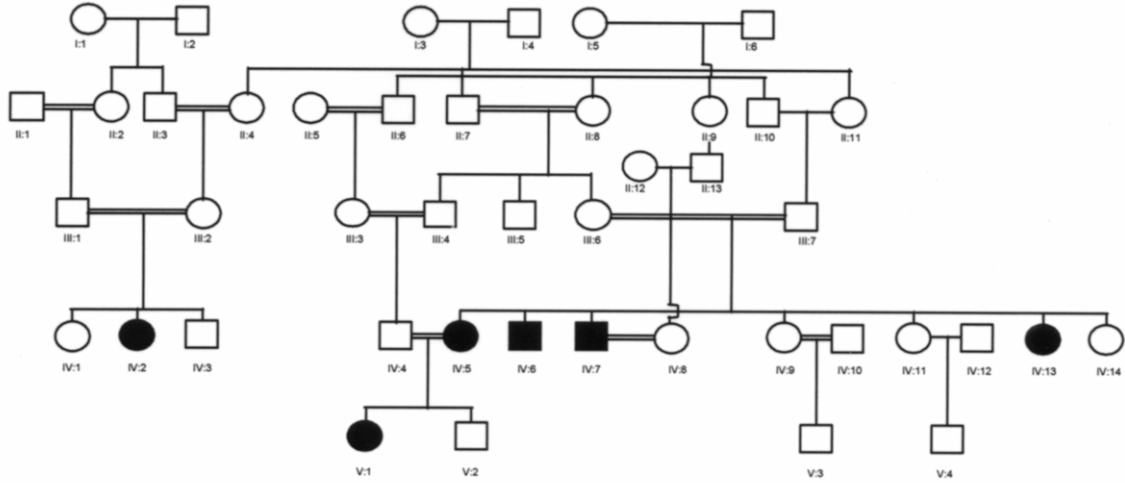
V:1 has been followed by an ophthalmologist throughout her life. At age 16 years, she has golden hair, pale skin that does not tan, hazel-blue irises, pendular nystagmus, iris transillumination, foveal hypoplasia, exotropia, moderate myopic astigmatism, and VA 6/36 in each eye.

IV:13 also received a diagnosis of “oculocutaneous albinism,” because she had silver/gold hair and skin hypopigmentation with inability to tan, pale hazel irises, pendular nystagmus, iris transillumination, foveal hypoplasia, mild hypermetropic astigmatism, and RVA 6/60 and LVA 6/36. After the birth of her first child at age 22 years, she bled excessively from an episiotomy wound and required a blood transfusion. A few months later, major vaginal bleeding occurred that required hospital management. Hematological review at age 26 years elicited a history of lifelong easy bruising, menorrhagia since menarche, excessive bleeding following incision and drainage of a dental abscess, and excessive bleeding following gum surgery. Full blood count demonstrated microcytosis (mean cell volume 67.6 femtoliters [fl] [normal range 78–99 fl]; mean cell hemoglobin [MCH] 21.9 pg [normal 27.0–32.0 pg]; MCH concentration 32.4 g/dl [normal 31.5–26.5 g/dl]) but no other abnormalities (platelet count  $1.98 \times 10^{11}$  platelets/liter).

A skin sample from the scalp of IV:7 was processed for transmission electron microscopy largely as described elsewhere (Eady 1985) (see fig. 2). The number of epidermal melanocytes appeared normal, although some of the cells were unusually small. Individual melanocytes contained multiple fully melanized melanosomes that were mainly small and round or ovoid, with a vesicular or granular matrix. In ~50% of basal keratinocytes that were adjacent to melanocytes, melanosomes were contained in membrane-bound aggregates. The number and size of the aggregates were variable, but aggregates contained up to 12 melanosomes. The peripheral cytoplasm of the keratinocytes adjacent to the melanocytes appeared edematous.

Platelet aggregation and secretion assays were under-

**A**



**B**

SNP ID	Physical distance (bp)	Genetic distance (cM)	IV:7		IV:5		IV:13	
10168	16332871		A	A	A	B	A	A
10169	19428248	46.0347043	B	B	B	B	B	B
10170	22007281	47.6558236	A	A	A	A	A	A
10171	24132342	47.9166677	B	B	B	B		
10172	33176984	48.9706644	A	A	A	A		
10173	33209953	48.9894894	B	B	B	B	B	B
10174	34760332	50.131789	B	B	B	B	B	B
10175	34760733	50.1326936	B	B	B	B	B	B
7461	36006096	52.6385816						
10176	36191414	53.0000163	B	B	B	B	B	B
10156	36346051	53.3016124	A	A	A	A	A	A
5208	36380994	53.3697634						
10177	36390581	53.3884614	A	A	A	A	A	A
10178	36390923	53.3891284	A	A	A	A	A	A
10179	36695508	53.8741793	A	A	A	A	A	A
10040	37946718	55.8086621	B	B	B	B	B	B
10180	39368378	57.9826517	A	A	A	A	A	A
10181	39375875	57.9969461						
4441	40030096	59.4016958	B	B	B	B	B	B
3451	40771776	61.8279602	B	B	B	B	B	B
10182	42122663	63.3859534	A	A	A	A	A	A
9812	42138787	63.3889084						
10183	43186344	63.5825267			B	B		
10184	46260460	67.0137169	A	A	A	A	A	A
4007	46822616	68.2988688	A	A	A	A	A	A
8879	46844069	68.3479128	A	B			A	B
10185	47046784	68.4792896						
10186	48163405	68.9155698	B	B	B	B	B	B
9655	49542393	70.9485995						
10187	51160543	73.4983391	B	B	B	B	B	B
10188	52292281	75.2316046	B	B	B	B	B	B
10189	52292441	75.2317625	A	A	A	A	A	A
10190	52977975	76.0794264			B	B		
10191	53325976	77.1049302	A	A	A	A	A	A
10192	53340283	77.1501676	A	A	A	A	A	A
10193	53558026	77.8386504	B	B	B	B	B	B
5831	55547747	82.7672107	A	A	A	A	A	A
10194	56275748	86.0943128	B	B	B	B	B	B
10195	56276410	86.0975869	B	B	B	B	B	B
10196	56763284	88.5055487			B	B		
5876	56763379	88.5060186	B	B	B	B	B	B
1265	57032873	89.8388712						
10197	57313456	91.1654868	AB	AB	AB	AB	AB	AB

← **BLOC1S3**

taken in two affected family members (IV:13 and IV:6) and a volunteer who had not taken medication in the past 10 d, by use of 50-ml blood samples and sodium citrate (4%) as anticoagulant (9:1). Platelet aggregation and ATP secretion were monitored in platelet-rich plasma (PRP) by use of a dual Chronolog lumi-aggregometer (Atkinson et al. 2001). PRP was incubated in the presence of luciferin-luciferase reagent before agonist addition. ATP secretion in response to collagen, adenosine diphosphate (ADP), adrenaline, thrombin receptor-activating peptide (TRAP), and arachidonic acid was abolished in both affected individuals, whereas a robust response to all five agonists was observed in the control (fig. 3A and data not shown). The delay in secretion response to adrenaline in the control coincides with onset of secondary wave aggregation, whereas secretion and secondary wave aggregation were absent in the two patients (fig. 3A). The absence of secretion is consistent with the absence of dense granules in the two patients—determined using electron microscopy (data not shown)—a feature that is characteristic of HPS. Both patients exhibited an impaired platelet-aggregation response to low concentrations of collagen, TRAP, and arachidonic acid and an absence of secondary wave aggregation response to adrenaline. The impairment in aggregation was overcome by high concentrations of TRAP (fig. 3A) and arachidonic acid, although there was still a marked reduction in response to collagen (data not shown). In contrast, the dose response curve to ADP for aggregation for one of the patients was similar to that observed in the control, whereas the other patient exhibited irreversible aggregation response to ADP only at concentrations in excess of 10  $\mu$ M (not shown). The relatively normal aggregation response to ADP is consistent with the defect in aggregation to the other platelet agonists being caused by the absence of dense-granule secretion rather than by the impairment of ADP-mediated receptor activation.

Platelet aggregation was further monitored after perfusion of whole blood on collagen as described elsewhere (Auger et al. 2005). As shown in figure 3B, platelets from a control donor exhibited formation of large platelet aggregates on collagen after perfusion for 4 min. In contrast, a dramatic reduction in platelet aggregate size was observed in the two *BLOC1S3* donors, consistent with the recognized role of secreted ADP in supporting thrombus formation under arterial rates of flow (Kuijpers et al. 2003). The defect in platelet aggregation under

---

The figure is available in its entirety in the online edition of *The American Journal of Human Genetics*.

---

**Figure 2** Slit-lamp examination of the proband (IV:7) and transmission electron micrograph. The legend is available in its entirety in the online edition of *The American Journal of Human Genetics*.

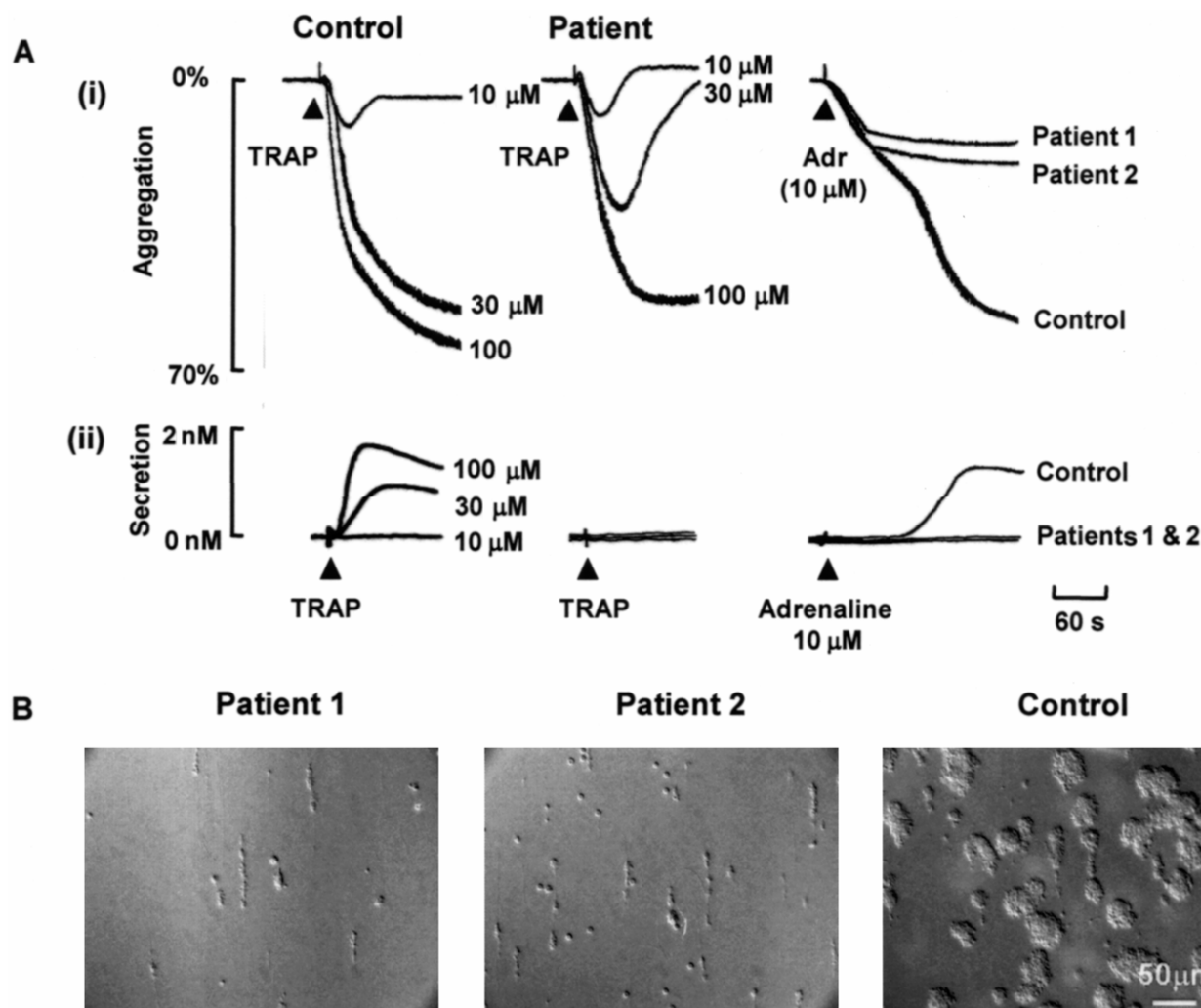
flow conditions is likely to account for the bleeding history of the two patients.

A genomewide linkage scan was performed using the Affymetrix 10K SNP chip in three affected individuals with HPS (IV:5, IV:7, and IV:13) (MRC GeneService). Three regions of extended homozygosity shared by all three individuals were identified and further analyzed by typing microsatellite markers in all family members from whom DNA was available. A common region of homozygosity was apparent in all affected members for a single marker, *D19S902*. This gave a minimal candidate region of 5.6 Mb between markers *D19S559* and *D19S246* on chromosome 19q13. We noted that the human homologue of the gene disrupted in the *rp* mouse, *BLOC1S3*, mapped to the target interval (see fig. 1B), and we proceeded to screen for a *BLOC1S3* germline mutation. The single coding exon was PCR amplified (details available on request) and was sequenced from forward and reverse strands on an ABI 3730 DNA analyzer. This revealed that all affected individuals were homozygous for a 1-bp frameshift deletion, c.448delC (see fig. 4). In the absence of nonsense-mediated decay, the mutation was predicted to specify an abnormal 224-aa protein (p.Gln150ArgfsX75; wild-type *BLOC1S3* protein is 203 aa). Sequencing of all family members demonstrated that the mutation segregated completely with the disease haplotype, and the mutation was not found in 210 ethnically matched control chromosomes.

To investigate possible mechanisms whereby the c.448delC mutation might impair *BLOC1S3* function, wild-type and mutant *BLOC1S3* coding sequences were cloned into a pEGFP-C2 expression vector (BD Biosciences Clontech) and were expressed in mouse malignant melanoma cells (F1P43 cell-line, a generous gift from Dr. Elena Sviderskaya, George's Hospital Medical School, University of London) (full details available on request). Phase-contrast microscopy demonstrated that wild-type *BLOC1S3* (aa 1–203) was expressed in the cytoplasm, but mutant, green fluorescent protein (GFP)-labeled

---

**Figure 1** A, Pedigree of consanguineous family from Pakistan with HPS. Blackened symbols represent patients affected with HPS. B, Genotyping results of SNP GeneChip mapping 10K (Affymetrix) array on chromosome 19q in three individuals affected with HPS. Homozygous genotypes are shaded in gray, heterozygous genotypes are unshaded, and black indicates no call. The position of *BLOC1S3* is shown.



**Figure 3** Platelet aggregation and secretion studies. *A*, Samples from the control and from a patient with *BLOC1S3* mutation were exposed to TRAP or adrenaline (Adr), and aggregation (i) and ATP secretion (ii) were monitored for 5 min. A similar set of results for TRAP was observed in the other patient (not shown). *B*, A 5-ml sample of whole blood anticoagulated with P-Pack solution 40 μM (9:1) was perfused over immobilized collagen for 4 min before perfusion with HEPES buffer for 5 min. Platelet aggregates were monitored using differential interference contrast microscopy with a  $\times 20$  lens. The results are representative of at least 10 different fields of view.

*BLOC1S3* protein (aa 1–224) localized in the nucleus (fig. 4).

We describe a large family with HPS caused by a homozygous frameshift mutation in *BLOC1S3*. To our knowledge, this has not been previously described in human HPS, and so the *BLOC1S3* mutation represents the eighth known type of HPS in humans. HPS is a rare disorder, but HPS1 has high prevalence in northwest Puerto Rico (1/1,800) because of a founder mutation (Witkop et al. 1990). Although we describe a single family, we excluded linkage to *BLOC1S3* in two other HPS-affected families of Asian origin (data not shown), and Gwynn et al. (2004) did not find *BLOC1S3* mutations in a total of 15 probands with HPS, which suggests that this is an infrequent cause of HPS.

Although the cardinal features of HPS—hypopigmentation, impaired VA, and platelet dysfunction—were present in this family, the bleeding tendency had not been clinically apparent in some individuals. To date, no affected individuals have shown clinical evidence of granulomatous colitis or pulmonary fibrosis. Colitis has been reported in HPS1, HPS3, and HPS4 but not HPS6, and pulmonary fibrosis in HPS1 and HPS4 but not HPS6 and HPS7 (Hermos et al. 2002; Anderson et al. 2003). Thus, it would appear that HPS1 and HPS4 are associated with a more severe phenotype than that seen in our family with HPS8. Interestingly, the *rp* mouse demonstrates coat hypopigmentation, increased bleeding time, and a reduced number of platelet-dense bodies, but both *rp* and *gunmetal* mice are unusual because their

---

The figure is available in its entirety in the online edition of *The American Journal of Human Genetics*.

---

**Figure 4** Wild-type and mutant *BLOC1S3* sequence traces and localization patterns of wild-type and mutant proteins in malignant melanoma cells. The legend is available in its entirety in the online edition of *The American Journal of Human Genetics*.

eye pigment formation is normal (Swank et al. 1998; Gwynn et al. 2004). These findings would suggest that *BLOC1S3* mutations are associated with a phenotype milder than some other types of HPS. Elsewhere, it was noted that, in mouse models of HPS, mutations in genes for BLOC-1 components (e.g., *pallid*, *cappuccino*, *muted*, and *sandy*) were associated with more-severe effects on coat color than mutations in genes for BLOC-3 components (*pale-ear/HPS1* and *light ear/HPS4*) (Li et al. 2004). The *rp* mouse displays an intermediate coat color. Thus, comparison of HPS subtype phenotypes in humans and mice demonstrates little correlation between severity of effect on coat color and occurrence of colitis and pulmonary fibrosis in humans, suggesting that different HPS protein complexes may affect distinct vesicle-trafficking pathways and have tissue-specific effects.

In mouse models of HPS, the hypopigmentation is mainly attributed to abnormal steps in the biogenesis of melanosomes, and the morphological differences in skin biopsies may be detected in different mouse models of HPS (Nguyen et al. 2002). Studies of human HPS are limited, although we found that, in our patient (IV:7), there did not appear to be an increase in the number of premelanosomes but melanosome aggregation was present. Although aggregates containing up to 2–6 melanosomes are normal in the skin of whites and Asians (Chinese), the aggregates in our patient comprised an unusually high number of melanosomes, suggesting a possible abnormality in transfer or packaging of these organelles. We note that a patient with compound heterozygote mutations in the *HPS1* gene was described as having “giant melanosomes” in his melanocytes and keratinocytes both in vivo and in culture (Horikawa et al. 2000).

The BLOC-1 complex is ubiquitously expressed and contains BLOC1S3 and seven predicted coiled-coil-forming proteins (Pallidin, Muted, Cappuccino, Dysbindin/HPS7, Snapin, BLOC1S1, and BLOC1S2) (Dell’Angelica 2004). Human *BLOC1S3* encodes a 203-aa protein, and, in the mouse, wild-type *rp* encodes a 195-aa protein. Mouse and human orthologues are 87% identical, and no orthologues have been described in yeast, flies, or worms (Gwynn et al. 2004). Although BLOC1S3 differs from other known BLOC-1 components in not having a predicted coiled-coil domain, an unstructured

amino terminal domain is followed by a domain with a high  $\alpha$ -helical content, similar to that seen in Dysbindin/HPS7/sandy. The precise function of the BLOC-1 complex in vesicular transport is unknown, although Snapin has been reported to interact with SNAP-23 and SNAP-25, and Pallidin with Syntaxin 13; thus, it has been suggested that BLOC-1 may regulate SNARE complex formation at some step in the endocytic pathway (Starcevic and Dell’Angelica 2004). We identified a frameshift mutation in our family, and mutant *rp/rp* mice have a premature stop codon that is predicted to truncate the *bloc1s3/rp* protein at 79 aa. Although we cannot exclude nonsense-mediated decay in our family, and no evidence of it was found in *rp* mice (Gwynn et al. 2004), our findings suggest that the domains distal to codon 150 are critical for normal BLOC1S3 protein function.

## Acknowledgments

We thank the Birmingham Children’s Hospital Research Foundation, the Wellcome Trust, and the British Heart Foundation, for financial support; Jocelyn Auger, for performing the flow studies over a collagen surface; and Trish Dopping-Hepenstal, for help with the skin electron microscopy.

## Web Resource

The URL for data presented herein is as follows:

Online Mendelian Inheritance in Man (OMIM), <http://www.ncbi.nlm.nih.gov/Omim/> (for HPS, *HPS1*, *AP3B1/HPS2*, *HPS3*, *HPS4*, *HPS5*, *HPS6*, and *HPS7/Dysbindin*)

## References

- Anderson PD, Huizing M, Claassen DA, White J, Gahl WA (2003) Hermansky-Pudlak syndrome type 4 (HPS-4): clinical and molecular characteristics. *Hum Genet* 113:10–17
- Atkinson BT, Stafford MJ, Pears CJ, Watson SP (2001) Signalling events underlying platelet aggregation induced by the glycoprotein VI agonist convulxin. *Eur J Biochem* 268:5242–5248
- Auger JM, Kuijpers MJ, Senis YA, Watson SP, Heemskerk JW (2005) Adhesion of human and mouse platelets to collagen under shear: a unifying model. *FASEB J* 19:825–827
- Davies BH, Tuddenham EGD (1976) Familial pulmonary fibrosis associated with oculocutaneous albinism and platelet function defect: a new syndrome. *Quart J Med* 45:219–232
- Dell’Angelica EC (2004) The building BLOC(k)s of lysosomes and related organelles. *Curr Opin Cell Biol* 16:458–464
- Dell’Angelica EC, Shotelersuk V, Aguilar RC, Gahl WA, Bonifacino JS (1999) Altered trafficking of lysosomal proteins in Hermansky-Pudlak syndrome due to mutations in the beta 3A subunit of the AP-3 adaptor. *Mol Cell* 3:11–21
- Eady RAJ (1985) Transmission electron microscopy. In: Skerrow D, Skerrow C (eds) *Methods in skin research*. John Wiley, London, pp 1–36
- Falcon-Perez JM, Starcevic M, Gautam R, Dell’Angelica EC (2002) BLOC-1, a novel complex containing the pallidin and muted proteins involved in the biogenesis of melanosomes and platelet-dense granules. *J Biol Chem* 277:28191–28199
- Gwynn B, Martina JA, Bonifacino JS, Sviderskaya EV, Lamoreux ML,

- Bennett DC, Moriyama K, Huizing M, Helipp-Wooley A, Gahl WA, Webb LS, Lambert AJ, Peters LL (2004) Reduced pigmentation (*rp*), a mouse model of Hermansky-Pudlak syndrome, encodes a novel component of the BLOC-1 complex. *Blood* 104:3181–3189
- Hermansky F, Pudlak P (1959) Albinism associated with hemorrhagic diathesis and unusual pigmented reticular cells in the bone marrow: report of two cases with histochemical studies. *Blood* 14:162–169
- Hermos CR, Huizing M, Kaiser-Kupfer MI, Gahl WA (2002) Hermansky-Pudlak syndrome type 1: gene organization, novel mutations, and clinical-molecular review of non-Puerto Rican cases. *Hum Mutat* 20:482
- Horikawa T, Araki E, Fukai K, Ueda M, Ueda T, Ito S, Ichihashi M (2000) Heterozygous *HPS1* mutations in a case of Hermansky-Pudlak syndrome with giant melanosomes. *Br J Dermatol* 143:635–640
- Kuijpers MJ, Schulte V, Bergmeier W, Lindhout T, Brakebusch C, Oferrmanns S, Fassler R, Heemskerk JW, Nieswandt B (2003) Complementary roles of glycoprotein VI and  $\alpha 2\beta 1$  integrin in collagen-induced thrombus formation in flowing whole blood ex vivo. *FASEB J* 17:685–687
- Li W, Rusiniak ME, Chintala S, Gautam R, Novak EK, Swank RT (2004) Murine Hermansky-Pudlak syndrome genes: regulators of lysosome-related organelles. *Bioessays* 26:616–628
- Nguyen T, Novak EK, Kermani M, Fluhr J, Peters LL, Swank RT, Wei ML (2002) Melanosome morphologies in murine models of Hermansky-Pudlak syndrome reflect blocks in organelle development. *J Invest Dermatol* 119:1156–1164
- Sandberg-Gertzén H, Eid R, Jarnerot G (1999) Hermansky-Pudlak syndrome with colitis and pulmonary fibrosis. *Scand J Gastroenterol* 34:1055–1056
- Schinella RA, Greco MA, Cobert BL, Denmark LW, Cox RP (1980) Hermansky-Pudlak syndrome with granulomatous colitis. *Ann Intern Med* 92:20–23
- Starcevic M, Dell'Angelica EC (2004) Identification of Snapin and three novel proteins (BLOS1, BLOS2, and BLOS3/reduced pigmentation) as subunits of biogenesis of lysosome-related organelles complex-1 (BLOC-1). *J Biol Chem* 279:28393–28401
- Swank RT, Novak EK, McGarry MP, Rusiniak ME, Feng L (1998) Mouse models of Hermansky-Pudlak syndrome: a review. *Pigment Cell Res* 11:60–80
- Witkop CJ, Nunez Babcock M, Rao GHR, Gaudier F, Summers CG, Shanahan F, Harmon KR, Townsend D, Sedano HO, King RA, Cal SX, White JG (1990) Albinism and Hermansky-Pudlak syndrome in Puerto Rico. *Bol Asoc Med P R* 82:333–339